



## Split face comparison between single band and dual band pulsed light technology for treatment of photodamage

Neal Varughese, Lauren Keller & David J. Goldberg

To cite this article: Neal Varughese, Lauren Keller & David J. Goldberg (2016): Split face comparison between single band and dual band pulsed light technology for treatment of photodamage, Journal of Cosmetic and Laser Therapy, DOI: [10.1080/14764172.2016.1177188](https://doi.org/10.1080/14764172.2016.1177188)

To link to this article: <http://dx.doi.org/10.1080/14764172.2016.1177188>



Accepted author version posted online: 16 May 2016.  
Published online: 16 May 2016.



Submit your article to this journal [↗](#)



View related articles [↗](#)



View Crossmark data [↗](#)



## Split face comparison between single band and dual band pulsed light technology for treatment of photodamage

Neal Varughese, Lauren Keller, and David J. Goldberg

Doi: 10.1080/14764172.2016.1177188

### ABSTRACT

**Background:** Intense Pulse Light (IPL) has a well-recognized role in the treatment of photodamaged skin. **Objective:** To assess the safety and efficacy of a novel single band IPL hand piece vs dual band hand IPL piece in the treatment of photodamage. **Study Design/Materials and Methods:** This was a prospective, single-center split-face study with 20 participants enrolled. Subjects were administered three treatments, 21 days apart and follow-up continued for 20 weeks. The left side of the face was treated with the single band hand piece. The right side of the face was treated with the dual band hand piece. Blinded investigators assessed the subjects' skin texture, pigmented components of photodamage, and presence of telangiectasia both pre- and post-treatment, utilizing a five point scale. **Results:** Pigmented components of photodamage, skin texture and presence of telangiectasias on the left and right side of the face were improved at the conclusion of treatment. At 20 week follow up, the side treated with single band hand piece showed a level of improvement in telangiectasia and pigmentation that was statistically superior to the contralateral side treated with the dual band hand piece. Both devices equally improved textural changes. No adverse effects were noted with either device. **Conclusion:** Both single band and dual band IPL technology are safe and effective in the treatment of photodamaged facial skin. Intense pulsed light treatment with a single band hand piece yielded results comparable or superior to dual band technology.

© 2016 Taylor and Francis. This provisional PDF corresponds to the article as it appeared upon acceptance. Fully formatted PDF and full text (HTML) versions will be made available soon.

DISCLAIMER: The ideas and opinions expressed in the journal's *Just Accepted* articles do not necessarily reflect those of Taylor and Francis (the Publisher), the Editors or the journal. The Publisher does not assume any responsibility for any injury and/or damage to persons or property arising from or related to any use of the material contained in these articles. The reader is advised to check the appropriate medical literature and the product information currently provided by the manufacturer of each drug to be administered to verify the dosages, the method and duration of administration, and contraindications. It is the responsibility of the treating physician or other health care professional, relying on his or her independent experience and knowledge of the patient, to determine drug dosages and the best treatment for the patient. *Just Accepted* articles have undergone full scientific review but none of the additional editorial preparation, such as copyediting, typesetting, and proofreading, as have articles published in the traditional manner. There may, therefore, be errors in *Just Accepted* articles that will be corrected in the final print and final online version of the article. Any use of the *Just Accepted* articles is subject to the express understanding that the papers have not yet gone through the full quality control process prior to publication.

# Split face comparison between single band and dual band pulsed light technology for treatment of photodamage

Neal Varughese<sup>1</sup>, Lauren Keller<sup>2</sup>, and David J. Goldberg<sup>1,3,4</sup>

<sup>1</sup>Skin Laser and Surgery Specialists of New York and New Jersey, <sup>2</sup>Palisades Medical Center, North Bergen, NJ, <sup>3</sup>Department of Dermatology, Mt. Sinai School of Medicine, New York, NY, <sup>4</sup>Dermatology, UMDNJ-Rutgers Medical School, Newark, NJ

**Corresponding author:** Neal Varughese, Skin and Laser Surgery Specialists of New York and New Jersey, NJ 07601, USA. Email: [JCLTadmin@skinandlasers.com](mailto:JCLTadmin@skinandlasers.com)

## ABSTRACT

**Background:** Intense Pulse Light (IPL) has a well-recognized role in the treatment of photodamaged skin. **Objective:** To assess the safety and efficacy of a novel single band IPL hand piece vs dual band hand IPL piece in the treatment of photodamage. **Study Design/Materials and Methods:** This was a prospective, single-center split-face study with 20 participants enrolled. Subjects were administered three treatments, 21 days apart and follow-up continued for 20 weeks. The left side of the face was treated with the single band hand piece. The right side of the face was treated with the dual band hand piece. Blinded investigators assessed the subjects' skin texture, pigmented components of photodamage, and presence of telangiectasia both pre- and post-treatment, utilizing a five point scale. **Results:** Pigmented components of photodamage, skin texture and presence of telangiectasias on the left and right side of the face were improved at the conclusion of treatment. At 20 week follow up, the side treated with single band hand piece showed a level of improvement in telangiectasia and pigmentation that was statistically superior to the contralateral side treated with the dual band hand piece. Both devices equally improved textural changes. No adverse effects were noted with either device. **Conclusion:** Both single band and dual band IPL technology are safe and effective in the treatment of photodamaged facial skin. Intense pulsed light treatment with a single band hand piece yielded results comparable or superior to dual band technology.

## ARTICLE HISTORY

Received 22 January 2016

Accepted 4 April 2016

## **Introduction:**

Photodamaged skin is often characterized by irregular pigmentation, broken capillaries, uneven texture and rhytids as a consequence of long-term sun exposure. Several energy based devices have helped improve the cosmetic appearance of these lesions, including pulsed dye (PDL), 532 nm KTP, QS Ruby and QS Nd:YAG lasers, and Intense Pulsed Light (IPL) sources. Among the various technologies available, IPL has significantly advanced the treatment of photodamaged skin, due to its ability to target multiple aspects of photodamage. IPL devices work by converting electrical energy into optical energy. In most devices, electric current passes through a chamber filled with xenon gas. The output then passes through a hand piece that delivers non-coherent polychromatic light to the skin. A cooling method in the form of contact, cryogen spray, or forced refrigerated air protects the epidermis from damage. In the treatment of photodamaged facial skin, IPL operates on the well recognized principle of selective photothermolysis.[1] Because traditional IPL emits wavelengths in the visible and near-infrared spectrum (500 to 1200 nm), the broad range discharged from the device leads to the simultaneous emission of green, yellow, red, and infrared wavelengths allowing hemoglobin and melanin chromophores to be targeted concurrently.[2] Furthermore, this versatility can be an advantage, as the various absorption peaks of hemoglobin (Hb) can be successfully targeted with more than one wavelength.[3] To date, there are more than 10 different manufacturers producing various IPL devices.[4] The first IPL devices were introduced in the 1990s for the treatment of vascular lesions. Since their debut, IPL platforms have undergone multiple

refinements in wavelength filtration, fluence, pulse duration, and cooling systems. One customized modification is a dual band output spectrum (500 - 670, 870-1200 nm). The dual spectral bands selectively target the absorption peaks of hemoglobin and preferentially heat blood in the presence of melanin. As shown in Figure 1, the spectral shift to longer infrared wavelengths that occurs with longer pulse widths or reduced power density enables coagulation of blood vessels that are located deeper in the skin.[5]

Dual band IPL technology is limited by the requirement for greater fluence, which may increase the risk of adverse effects. Recently, a narrow or single-band output device (500–600 nm) was developed. As shown in Figure 2, this spectrum essentially narrows the optical absorbance spectrum of oxyhemoglobin and targets two peaks (542, 577 nm) for potentially greater precision and safety. In this study, we compared a novel single band hand piece versus a dual band hand piece for the treatment of photodamage. We report safety and efficacy results for a split-face comparison study in which subjects were treated with a single-band IPL and a dual-band IPL. Both devices were evaluated for their effectiveness in improving telangiectasia, pigmentation, and skin texture.

## **Materials and Methods**

### *Device Description*

The IPL single band hand piece (Dye-VL; Alma, Buffalo Grove, IL) is a lamp-based hand piece with single band spectral output in the 500 to 600 nm range.

Available pulse widths are 10, 12, and 15 milliseconds and fluence ranges from 1 to 13 J/cm<sup>2</sup>. Treatment area consists of a 3 cm<sup>2</sup> sapphire optical window with contact cooling (Table 1)

The IPL dual band hand piece (Max G; Palomar Medical Technologies, Inc., Burlington, MA) is a lamp-based hand piece with dual band spectral output (500-670, 870-1200 nm). Available pulses are from 5 to 100 milliseconds and fluence range from 5 to 85 J/cm<sup>2</sup>. Treatment area consists of a 10 mm by 15 mm sapphire optical window with contact cooling (Table 1).

### *Study Design*

Twenty participants, (2 males and 18 females), Fitzpatrick skin types I-III, with photodamage were enrolled, treated, and evaluated at single study site, Skin and Laser Surgery Specialists of New York and New Jersey, Hackensack, NJ.

Subject ages ranged from 55-75 years with a mean age of 62 years. All subjects provided signed informed consents under an irb approved protocol. Subjects were excluded if they had used oral retinoids within the past year, had a history of photosensitivity, or anticipated using other methods of skin rejuvenation within the treatment or follow-up period

All subjects received three treatments given 21 days apart. Each subject received a full-face treatment. The left side of the face was treated with the single band hand piece and the contralateral side was treated with the dual band hand piece. Ultrasound gel was applied to the face to aid with skin contact. Energies were delivered as a single pulse with the initial fluence, pulse width, and pulse delay increased as tolerated during subsequent treatments. Initial power and parameters of the devices were selected according to the Fitzpatrick skin type of the subject and the clinical severity of the subject's photodamage (Table 1).

Operator bias was minimized by having the same practitioner (Principal

Investigator) perform all laser treatments and a blinded practitioner (Procedural Dermatology Fellow) perform all assessments.

All subjects were evaluated and photographed at each treatment session as well as 20 weeks after the final treatment. Any improvement in pigmentation, perceived quality of skin texture and telangiectasia clearance were scored based on a scale of 0-4 (0, none; 1, barely visible and localized; 2, somewhat visible and diffuse; 3, visible and diffuse; 4, extremely visible and dense).

#### *Treatment parameters*

Fluences used with the single band handpiece were 10-12 J/cm<sup>2</sup> with a pulse width of 10-12 msec.

Fluences used with the dual band hand piece were 32-44 J/cm<sup>2</sup> with a pulse width of 30 msec.

#### *Statistical methods.*

A paired t-test statistical analysis was undertaken of both 1) pre-and 20 week post-treatment with both handpieces and 2) a comparison of data, between the 2 handpieces at 20 weeks post- treatment in terms of pigmentation, telangiectases and overall skin textural improvement.

### **Results**

#### *Safety*

Our results demonstrate that all treatments were well tolerated by study subjects. Although mild post –treatment erythema was noted with both devices, there was no observed vesiculation, crusting, or post treatment pigmentary alterations or scarring seen with either device.

#### *Efficacy*

Figures 3 to 5 show the overall scores for the two devices. Pigmented components of photodamage, skin texture, and presence of telangiectatic vessels on the left and right sides of the face were equivalent at baseline, and demonstrated statistically significant improvement with both devices at 20 weeks after treatment ( $p < .001$ ). However, as can be seen in Figures 3 and 4, at 20 week follow up, the single band treated side displayed statistically better clearance of pigmentation ( $p < .001$ ) and vessel clearance ( $p < .001$ ) as compared to the double band treated side. Improvement in skin texture was comparable with both devices (Figures 6-7) .

### **Discussion**

It is well established that IPL treatment is safe and effective in the treatment of various components of photodamage. Examples of telangiectasia clearance due to IPL include a 2001 study showing >50% clearance in 79% of subjects and a 2004 study showing >80% clearance in 67% of subjects.[6, 7] A 2012 study compared facial telangiectasia treated with PDL and IPL, and found equivalent clinical outcomes.[8] A study evaluating the effectiveness of IPL treatment for pigmented lesions showed pigment reduction in 96% of patients and an average clearance of 74.2% for solar lentigines. .[9] Additionally, several authors have shown IPL may effectively improve facial rhytids without epidermal ablation.[10-14]

Dual-band spectrum technology has increased the ability of these devices to target both superficial and deep vessels while minimizing epidermal damage.

Given the lack of side by side comparison studies of single-band versus dual



band technology, we decided to perform a split-face study to directly compare safety and efficacy

Here the results indicate that the single band yielded clinical outcomes comparable or superior to dual band technology in the improvement of photodamaged skin. We propose that there may be more precise vessel targeting with the single band hand piece given the narrowing emitted wavelengths to absorption peaks of oxyhemoglobin. Within this spectral band, the molar extinction coefficient for hemoglobin at 540 and 570 nanometers is 53 and 55  $M^{-1}cm^{-1}$ , respectively. At 600 nm, the molar extinction coefficient drops to 3.2  $mM^{-1} cm^{-1}$ . [15] Therefore, the single band handpiece is spectrally and optimally designed to target the middle of hemoglobin absorption peaks. The greater precision likely leads to better clinical outcomes.

In our study, significant adverse effects were not noted with either device. Potential adverse effects of intense pulsed light treatment include swelling, erythema, and blistering. Higher delivered fluences can increase the thermal effect on tissue, which can lead to undesired consequences, particularly for patients with darker skin types. [16] Due to the broader spectrum and lower average absorption coefficient of the targeted chromophores, dual-band spectrum technology requires higher energy than single-band technology for efficacy. In contrast, the single band hand piece generates lower total energy due to much narrower spectrum of emission. As has been noted by other investigators, patients experience less discomfort with lower delivered fluences, and side effects are less severe when fluence is decreased. [17] Accordingly, we

postulate that single band hand piece may confer a potential safety advantage for patients.

## Conclusion

In this study, both devices were safe and effective in the treatment of photodamaged facial skin. Intense pulsed light treatment with a single band hand piece yielded results comparable or superior to dual band technology.

## References

1. Anderson, R.R. and J.A. Parrish, *Selective photothermolysis: precise microsurgery by selective absorption of pulsed radiation*. Science, 1983. **220**(4596): p. 524-7.
2. Goldberg, D.J., *Current trends in intense pulsed light*. J Clin Aesthet Dermatol, 2012. **5**(6): p. 45-53.
3. Babilas, P., et al., *Intense pulsed light (IPL): a review*. Lasers Surg Med, 2010. **42**(2): p. 93-104.
4. Ciocon, D.H., A. Boker, and D.J. Goldberg, *Intense pulsed light: what works, what's new, what's next*. Facial Plast Surg, 2009. **25**(5): p. 290-300.
5. Weiss, R.A., et al., *Characterization of an optimized light source and comparison to pulsed dye laser for superficial and deep vessel clearance*. Lasers in Surgery and Medicine, 2011. **43**(2): p. 92-98.
6. Bjerring, P., K. Christiansen, and A. Troilius, *Intense pulsed light source for treatment of facial telangiectasias*. J Cosmet Laser Ther, 2001. **3**(4): p. 169-73.

7. Retamar, R.A., C. Chames, and G. Pellerano, *Treatment of linear and spider telangiectasia with an intense pulsed light source*. J Cosmet Dermatol, 2004. **3**(4): p. 187-90.
8. Tanghetti, E.A., *Split-face randomized treatment of facial telangiectasia comparing pulsed dye laser and an intense pulsed light handpiece*. Lasers Surg Med, 2012. **44**(2): p. 97-102.
9. Bjerring, P. and K. Christiansen, *Intense pulsed light source for treatment of small melanocytic nevi and solar lentigines*. J Cutan Laser Ther, 2000. **2**(4): p. 177-81.
10. Goldberg, D.J. and K.B. Cutler, *Nonablative treatment of rhytids with intense pulsed light*. Lasers Surg Med, 2000. **26**(2): p. 196-200.
11. Sadick, N.S., et al., *Photorejuvenation with intense pulsed light: results of a multi-center study*. J Drugs Dermatol, 2004. **3**(1): p. 41-9.
12. Bitter, P.H., *Noninvasive rejuvenation of photodamaged skin using serial, full-face intense pulsed light treatments*. Dermatol Surg, 2000. **26**(9): p. 835-42; discussion 843.
13. Weiss, R.A., M.A. Weiss, and K.L. Beasley, *Rejuvenation of photoaged skin: 5 years results with intense pulsed light of the face, neck, and chest*. Dermatol Surg, 2002. **28**(12): p. 1115-9.
14. Goldberg, D.J., *New collagen formation after dermal remodeling with an intense pulsed light source*. J Cutan Laser Ther, 2000. **2**(2): p. 59-61.
15. Zonios, G., J. Bykowski, and N. Kollias, *Skin melanin, hemoglobin, and light scattering properties can be quantitatively assessed in vivo using*

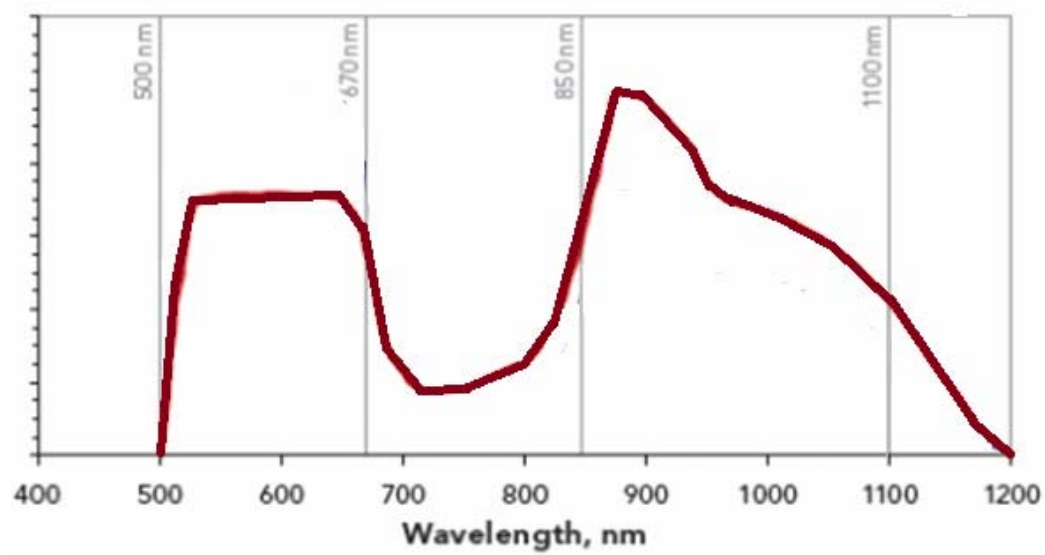
*diffuse reflectance spectroscopy*. *J Invest Dermatol*, 2001. **117**(6): p. 1452-7.

16. Belenky, I., C. Tagger, and A. Bingham, *Intense Pulsed Light Pulse Configuration Manipulation Can Resolve the Classic Conflict Between Safety and Efficacy*. *J Drugs Dermatol*, 2015. **14**(11): p. 1255-60.
17. Kligman, D.E. and Y. Zhen, *Intense pulsed light treatment of photoaged facial skin*. *Dermatol Surg*, 2004. **30**(8): p. 1085-90.

JUST ACCEPTED

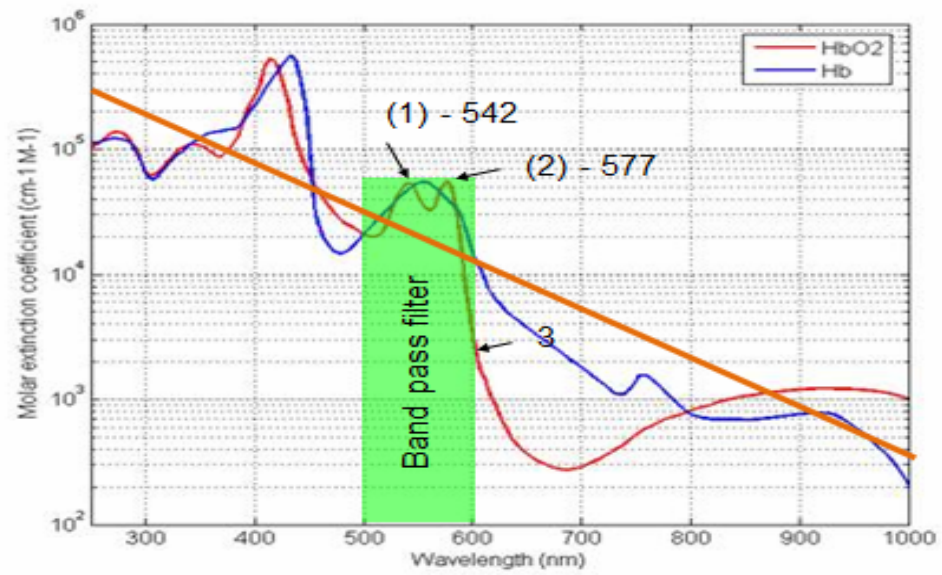
## Figure Legends

Figure 1: Dual Band Absorption Curve



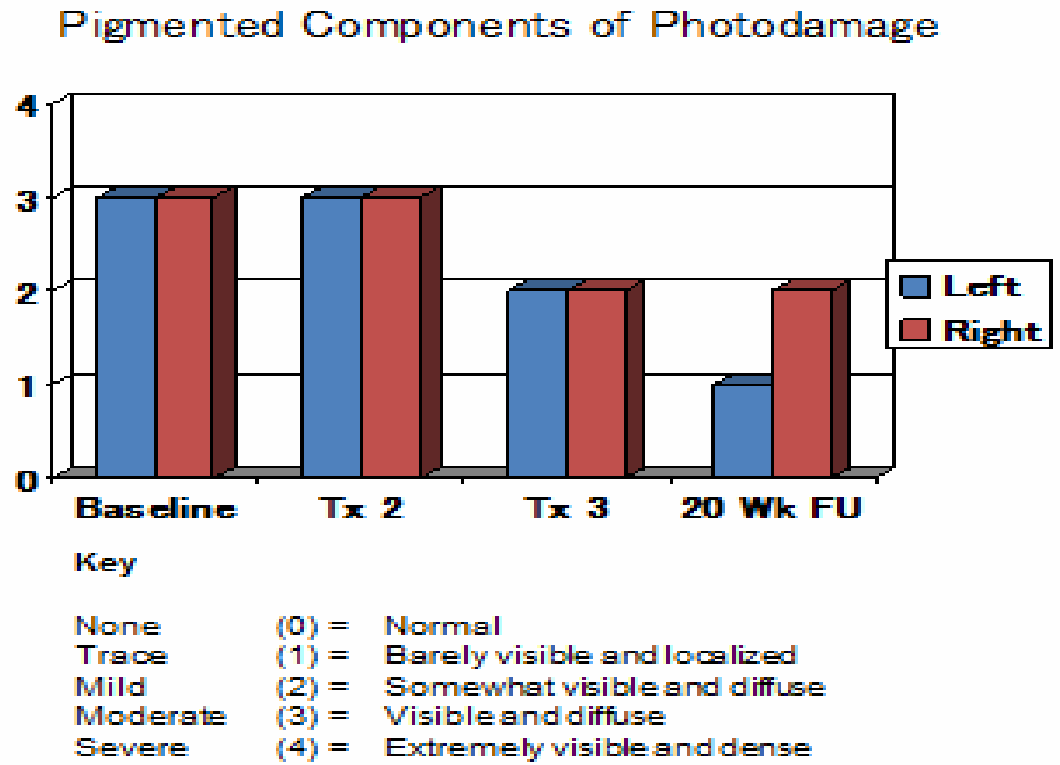
**Figure 2:** 500-600 nm wavelength is narrow band target 542 and 577 nm absorption peaks of hemoglobin

## Dye VL 500 oxyhemoglobin absorption



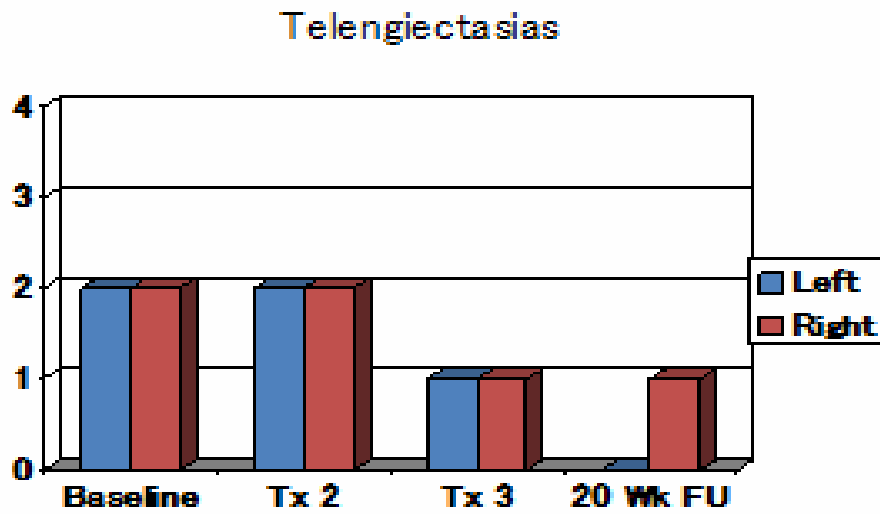
JUST ACCV

Figure 3: Distribution of Scores for Pigment-component of Photodamage following treatment Narrow Band IPL (Left) versus Dual Band IPL (Right)



JUST AC

Figure 4: Distribution of Scores for Telangiectasia-component of Photodamage following treatment Narrow Band IPL (Left) versus Dual Band IPL (Right)



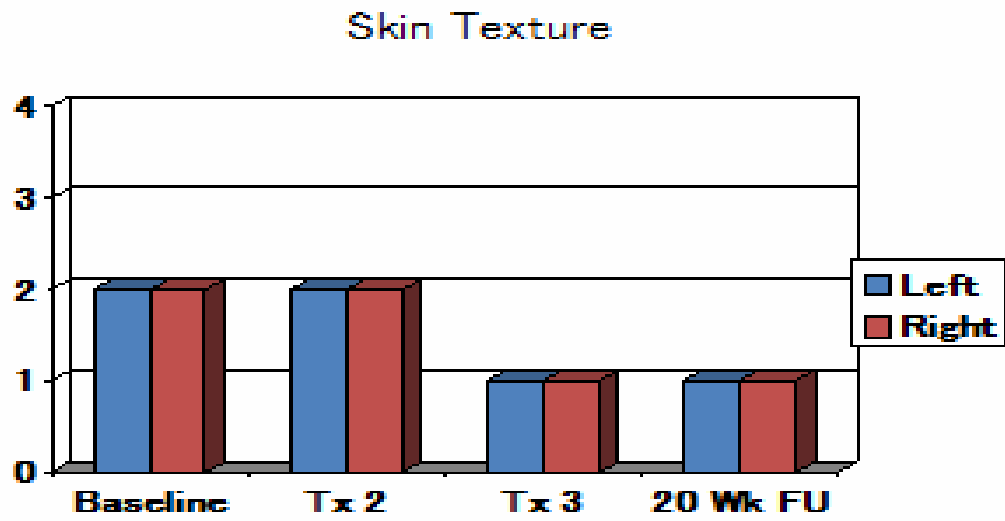
**Key**

- |          |       |                              |
|----------|-------|------------------------------|
| None     | (0) = | Normal                       |
| Trace    | (1) = | Barely visible and localized |
| Mild     | (2) = | Somewhat visible and diffuse |
| Moderate | (3) = | Visible and diffuse          |
| Severe   | (4) = | Extremely visible and dense  |

JUST A



Figure 5: Distribution of Scores for Skin texture-component of Photodamage following treatment Narrow Band IPL (Left) versus Dual Band IPL (Right)



**Key**

- |          |                                    |
|----------|------------------------------------|
| None     | (0) = Normal                       |
| Trace    | (1) = Barely visible and localized |
| Mild     | (2) = Somewhat visible and diffuse |
| Moderate | (3) = Visible and diffuse          |
| Severe   | (4) = Extremely visible and dense  |

JUST AC

Clinical Photographs

Figure 6: Photodamage prior to IPL treatment

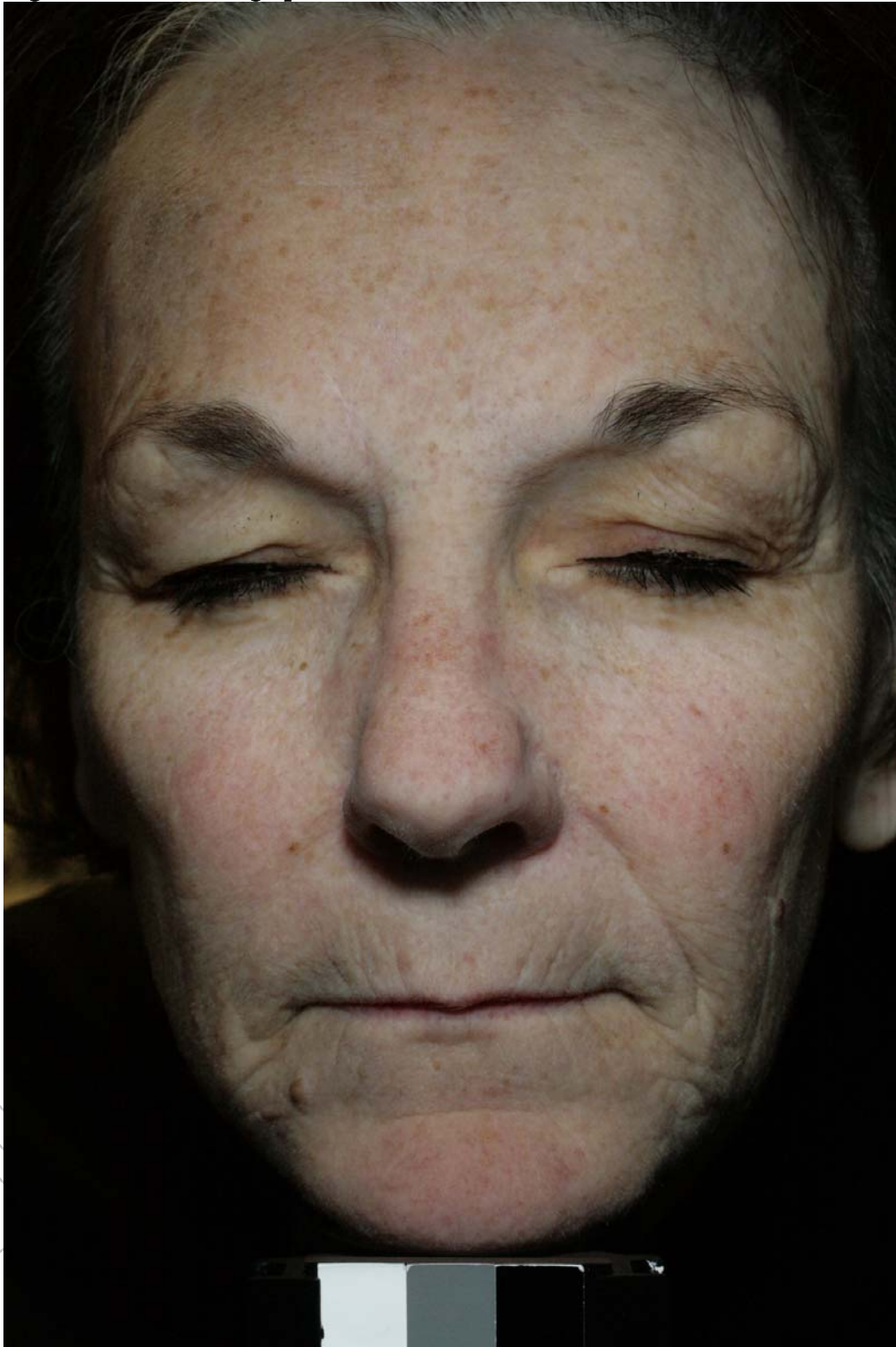
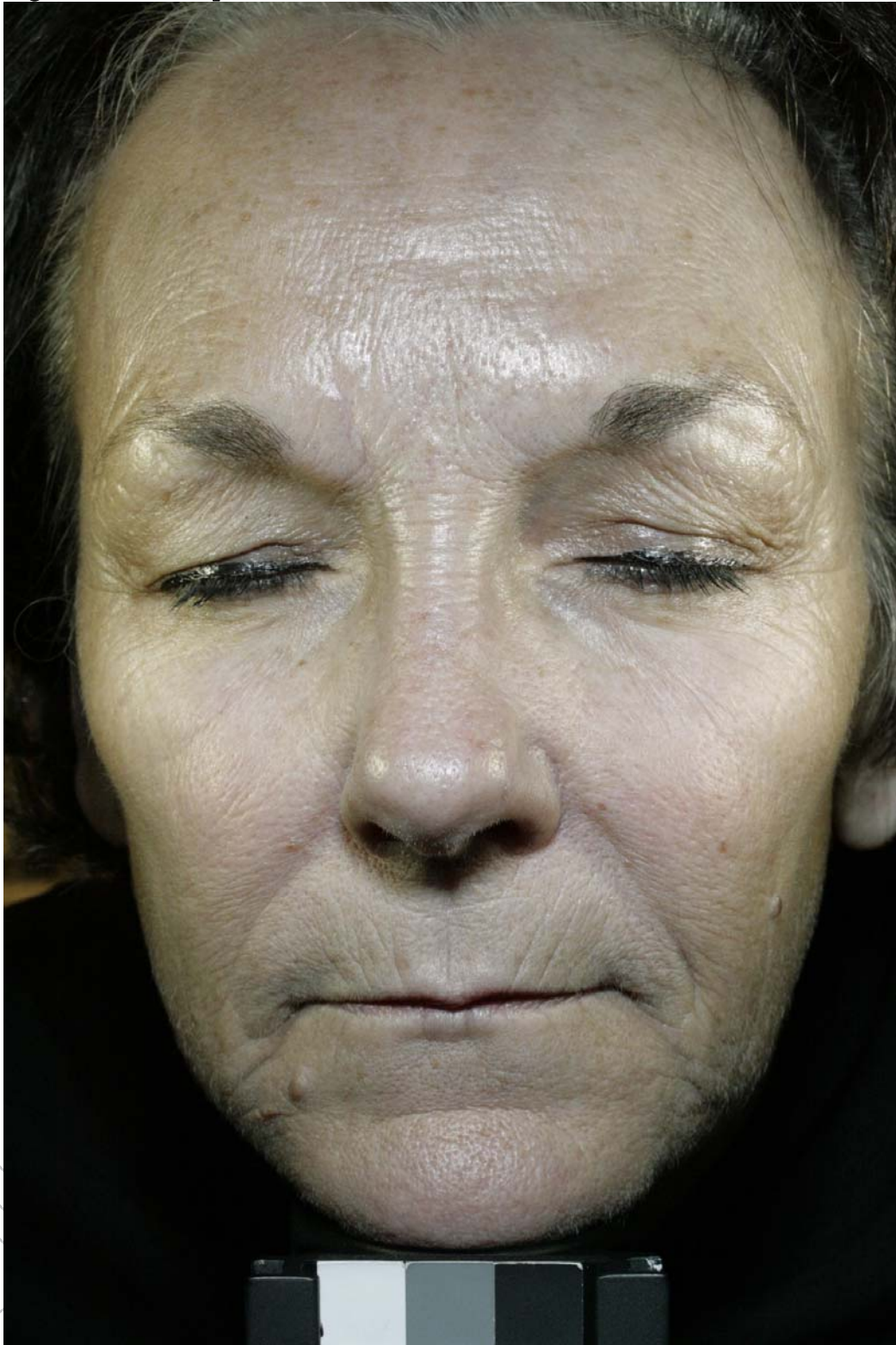


Figure 7: Note improvement in texture on both sides of face.



**Table Legends****Table 1: Single Band and Dual Band IPL Handpiece Specifications**

	Narrow Band IPL Specifications	Dual Band IPL Specifications
Spot size	3 cm <sup>2</sup>	10 mm x 15 mm
Spectral Range	500-600 nm	570-600 nm & 870-1200 nm
Pulse Duration	10, 12, 15 ms	5 to 100 ms
Fluence	1 to 13 J/cm <sup>2</sup>	5 to 85 J/Cm <sup>2</sup>
Sapphire Tip Temp	Room temperature to 5 degrees Celsius	Room temperature to 5 degrees Celsius

JUST ACCEPTED

**Table 2: Treatment parameters**

<b>Fitzpatrick Skin Type</b>	<b>Module</b>	<b>Pulse Width (msec)</b>	<b>Fluence (J/cm<sup>2</sup>)</b>
I-III	Single Band IPL	10, 12	10-12

<b>Fitzpatrick Skin Type</b>	<b>Module</b>	<b>Pulse Width (msec)</b>	<b>Fluence (J/cm<sup>2</sup>)</b>
I-III	Dual Band IPL	30	32-44

JUST ACCEPTED